CLINICAL PRACTICE

Acute Pulmonary Embolism

Stavros Konstantinides, M.D.

This Journal feature begins with a case vignette highlighting a common clinical problem. Evidence supporting various strategies is then presented, followed by a review of formal guidelines, when they exist. The article ends with the author's clinical recommendations.

A 62-year-old man presented with a 5-day history of progressively worsening dyspnea and orthopnea after returning from a 3-day business trip to the Far East. On physical examination, the heart rate was 102 beats per minute, and the blood pressure 110/60 mm Hg. The arterial oxygen saturation was 86% while the patient was breathing ambient air. The neck veins were distended. There was no heart murmur. The lungs were clear, and the extremities appeared normal. The D-dimer level was 5.13 mg per liter (normal level, less than 0.5), and the troponin T level was less than 0.01 μg per liter. A computed tomographic (CT) scan showed multiple thrombi in the pulmonary arteries and a dilated right ventricle. How should this case be managed?

THE CLINICAL PROBLEM

Acute pulmonary embolism is a major cause of complications and death associated with surgery, injury, and medical illnesses, and it may occur after long-distance air travel. Venous thromboembolism is responsible for up to 15% of all in-hospital deaths, and it also accounts for 20 to 30% of deaths associated with pregnancy and delivery in the United States and Europe. Overall, the annual incidence of pulmonary embolism has been reported to range between 23 and 69 cases per 100,000 population.[1,2] Case fatality rates vary widely depending on the severity of the disease[3,4]; at an average case fatality rate within 2 weeks of diagnosis of approximately 11%,[5] the Surgeon General estimates that venous thromboembolism accounts for at least 100,000 deaths each year.[6]

From the Department of Cardiology and Pulmonology, Georg August University of Göttingen, Göttingen, Germany. Address reprint requests to Dr. Konstantinides at the Department of Cardiology and Pulmonology, Georg August University School of Medicine, D-37099 Göttingen, Germany, or at skonstan@med.uni-goettingen.de.

N Engl J Med 2008;359:2804-13.
Copyright © 2008 Massachusetts Medical Society.

STRATEGIES AND EVIDENCE

DIAGNOSTIC APPROACH TO SUSPECTED PULMONARY EMBOLISM

The predisposing factors for and diagnostic evaluation of suspected pulmonary embolism have recently been reviewed in the *Journal*.[7] Individual symptoms such as dyspnea, chest pain, or cough; clinical signs such as tachypnea, tachycardia, or evidence of deep-vein thrombosis; and routine laboratory findings, including hypoxemia and hypocapnia, have low sensitivity and specificity for the diagnosis. Electrocardiographic and radiographic findings also have low sensitivity and specificity, although they are helpful in strengthening (or weakening) the clinical suspicion. Scores derived from explicit prediction rules that combine clinical findings at presentation with predisposing factors have proved useful in determining the clinical or pretest probability of pulmonary embolism. Use of the Wells score[8] or of the Geneva score[9] is recommended, since these scores may guide a further diagnostic workup and improve the interpretation of diagnostic test results (Fig. 1; and Table 1 in the Supplementary Appendix, available with the full text of this article at www.nejm.org).[13]

For patients who have a low or moderate pretest probability of pulmonary embolism, D-dimer testing is recommended as the next step in establishing a diagnosis.

Downloaded from www.nejm.org at UNIV MISSOURI on July 27, 2009 .
Copyright © 2008 Massachusetts Medical Society. All rights reserved.

A D-dimer level below 0.5 mg per liter, as assessed with the use of a highly sensitive enzyme-linked immunosorbent assay, reliably rules out the presence of circulating fibrin and thus essentially rules out a diagnosis of venous thromboembolism. Negative D-dimer results may eliminate the need for further diagnostic testing in almost 30% of patients with suspected pulmonary embolism.[9,14,15] However, a D-dimer test should not be used in patients with a high clinical probability of pulmonary embolism, since the negative predictive value of this test is low for these patients (Fig. 1).[16] Furthermore, D-dimer testing can be omitted as a diagnostic step in patients who are older than 80 years of age, are hospitalized, or have cancer, as well as in pregnant women, because D-dimer concentrations are frequently (and nonspecifically) elevated in such patients.

IMAGING OF THE LEG VEINS AND PULMONARY ARTERIES

A compression ultrasonographic examination detects proximal deep-vein thrombosis in about 20% of patients with pulmonary embolism, and the rate of detection is twice as high when the distal veins are also examined. A positive result essentially establishes the diagnosis of venous thromboembolism and can obviate the need for additional imaging studies. Furthermore, when performed in combination with single-detector CT angiography, leg-vein ultrasonography enhances the sensitivity of that procedure.[17]

Currently, most centers perform multidetector CT, which can reliably be used as a single imaging test to diagnose or rule out pulmonary embolism in the majority of cases (Fig. 1).[10,11,14] Multidetector CT also provides potentially useful prognostic information by permitting an assessment of the size of the right ventricle.[18,19] CT-based algorithms, which have been validated in prospective trials of the management of pulmonary embolism,[10,14] emphasize the need to consider the findings of this test in conjunction with an assessment of clinical probability and the results of D-dimer testing (Fig. 1). This strategy successfully guides management decisions in almost 98% of patients; the 3-month risk of a recurrence of venous thromboembolism among patients in whom this evaluation rules out pulmonary embolism is as low as 1%.[10] Combining CT pulmonary angiography and CT venography in a single procedure is generally not recommended, since that combination increases exposure to radiation without significantly enhancing the specificity or negative predictive value of CT angiography.[12,20]

Ventilation–perfusion lung scanning remains an alternative to CT angiography when injection of a contrast dye is a concern. A normal scan can rule out the disease, but the scan is normal in no more than about a third of patients with suspected pulmonary embolism,[21] whereas inconclusive findings are frequent. Therefore, a lung scan is generally not recommended as a single diagnostic test to confirm the presence of pulmonary embolism.[13] The use of selective pulmonary angiography has declined and is currently reserved for cases in which catheter-based treatment is an option. Currently, magnetic resonance imaging does not have adequate sensitivity for imaging distal branches of the pulmonary arteries and thus cannot be recommended yet as a test for suspected acute pulmonary embolism.

Patients with suspected pulmonary embolism who present with arterial hypotension or shock pose a particular challenge. The clinical probability is, as a rule, high, and immediate diagnosis and initiation of treatment can be lifesaving. Multidetector CT is the preferred diagnostic test in most hospitals. However, bedside echocardiography may be a valuable alternative if CT is not immediately available or if the patient's condition is too unstable for a transfer to the radiology department (Fig. 2).

TREATMENT OPTIONS

INITIAL ANTICOAGULATION

Anticoagulation with heparin should be initiated without delay in all patients with confirmed pulmonary embolism. It is also recommended for patients with an intermediate or high clinical probability of pulmonary embolism until the results of further diagnostic tests are available.[13,24] A meta-analysis of several major trials showed that low-molecular-weight heparins are at least as effective as unfractionated heparin in preventing a recurrence of symptomatic venous thromboembolism (3-month recurrence rate, 3.0% vs. 4.4%; odds ratio, 0.68; 95% confidence interval [CI], 0.42 to 1.09), and at least as safe with respect to the rate of major bleeding (1.3% vs. 2.1%; odds ratio, 0.67; 95% CI, 0.36 to 1.27).[25] Similar data were obtained with the use of the pentasaccharide fondaparinux.[26] Fondaparinux or low-molecular-weight heparins are currently preferred to unfractionated heparin because they are easier to administer and

Downloaded from www.nejm.org at UNIV MISSOURI on July 27, 2009 .
Copyright © 2008 Massachusetts Medical Society. All rights reserved.

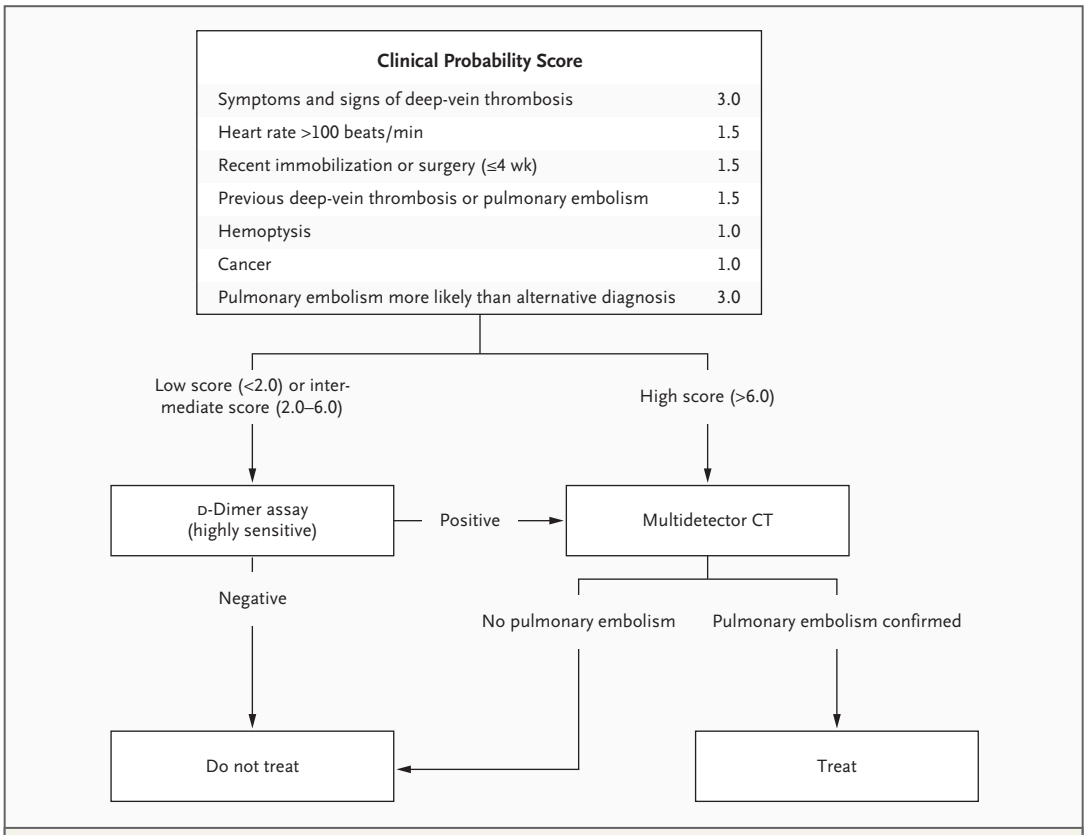

Figure 1. Diagnostic Algorithm for Suspected Pulmonary Embolism in a Patient without Hypotension or Shock. This assessment of clinical probability is based on the Wells score (which has a range of 0 to 12.5, with higher scores indicating higher clinical probability).[8] The revised Geneva score[9] may be used as an alternative (see Table 1 in the Supplementary Appendix). If a moderately sensitive latex-derived D-dimer assay is used instead of the highly sensitive enzyme-linked immunosorbent D-dimer assay, pulmonary embolism can be ruled out only in patients with a low clinical probability. Alternatively, the Wells score can be dichotomized, classifying pulmonary embolism as unlikely (≤4.0) or likely (>4.0). For patients in whom pulmonary embolism is considered unlikely, either a highly sensitive or a moderately sensitive D-dimer assay can be used to rule out the diagnosis without need for further testing.[10] If multidetector CT pulmonary angiography, with or without venography, is negative in a patient with a high clinical probability, the possibility of a false negative result should be considered, and further testing performed to rule out pulmonary embolism. Options include serial venous ultrasonography, ventilation–perfusion lung scanning, and pulmonary angiography.[11,12] If a multidetector CT scan shows only subsegmental defects in a patient with a low clinical probability, the possibility of a false positive result should be considered, and further testing (e.g., venous ultrasonography) should be performed to confirm the diagnosis.[11,12] This may also apply to patients with an intermediate clinical probability, although the need for further tests is less well established for these patients.[13]

are associated with lower rates of heparin-induced thrombocytopenia (see below).

The recommended doses of the heparins that are currently approved for the treatment of pulmonary embolism are shown in Table 1. Heparin treatment is continued for at least 5 to 6 days in combination with oral anticoagulation (vitamin K antagonists) until the international normalized ratio (INR) is within the therapeutic range (2.0 to 3.0) for 2 consecutive days.

The incidence and management of heparin-induced thrombocytopenia have been reviewed in the *Journal*[29] and in recent guidelines.[28] The risk of this potentially fatal complication (mortality, 8 to 20%) depends on both the type of heparin used and the clinical setting. The incidence is highest (3 to 5%) among patients who have undergone orthopedic surgery and received unfractionated heparin. Among medical and surgical patients receiving low-molecular-weight heparin, the incidence is less than 1%, and among patients receiving fondaparinux, the risk is negligible. The current recommendations for the monitoring of platelet counts during heparin treatment are sum-

Downloaded from www.nejm.org at UNIV MISSOURI on July 27, 2009 .
Copyright © 2008 Massachusetts Medical Society. All rights reserved.

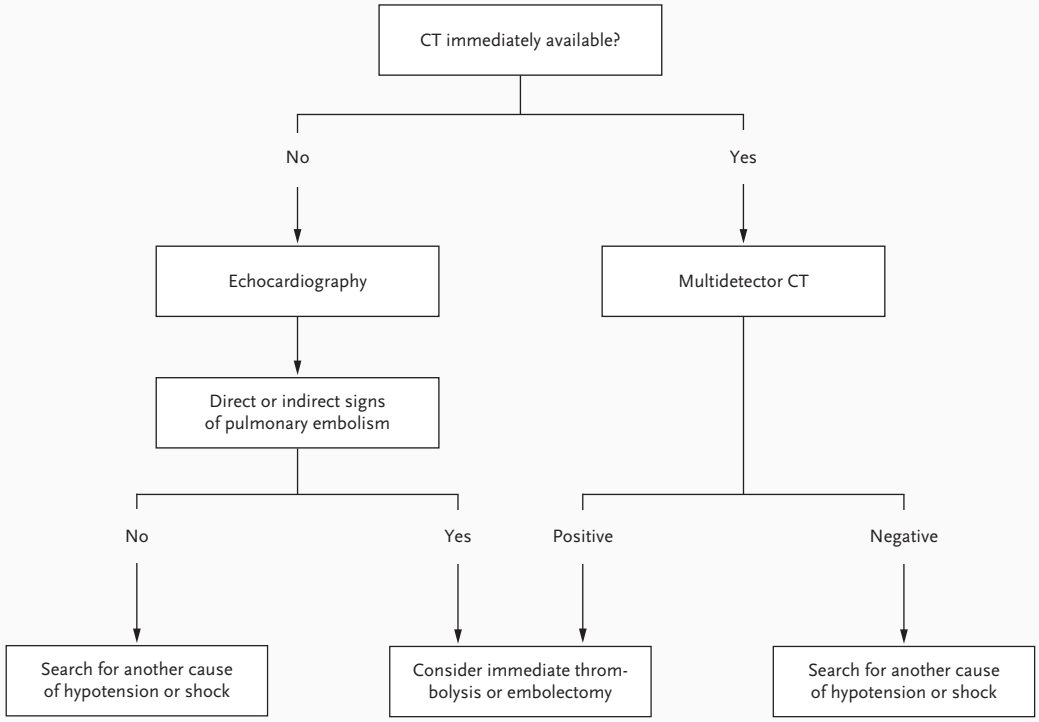

Figure 2. Emergency Diagnostic Workup for Suspected Pulmonary Embolism in a Patient with Hypotension or Shock.

A direct sign of pulmonary embolism on a transthoracic or transesophageal echocardiogram is the presence of thrombi in the right atrium, right ventricle, or pulmonary artery. Thrombi may protrude into the left atrium through a patent foramen ovale.[22] Indirect signs include right ventricular dysfunction (identified by the finding of dilatation, free-wall hypokinesia, or paradoxical septal-wall motion); a systolic pressure gradient between the right ventricle and the right atrium of more than 30 mm Hg; and a pulmonary arterial flow acceleration time of less than 80 msec.[23] When direct or indirect signs of pulmonary embolism are present, immediate treatment (without further diagnostic tests) is justified, particularly if CT angiography is still not available and arterial hypotension or shock persists. Adapted from the 2008 Guidelines on the Diagnosis and Management of Acute Pulmonary Embolism of the European Society of Cardiology.[13] Since validation of diagnostic algorithms in prospective trials excluded hemodynamically unstable patients, these recommendations reflect expert opinion.

marized in Table 1. When there is an intermediate or high clinical suspicion of heparin-induced thrombocytopenia, all sources of heparin should be discontinued, and therapy with direct parenteral thrombin inhibitors, particularly argatroban or lepirudin, should be initiated; bivalirudin is approved for patients undergoing percutaneous coronary interventions.

THROMBOLYSIS

Results from randomized trials[30] have shown that thrombolytic agents (e.g., urokinase, streptokinase, and alteplase) rapidly resolve thromboembolic obstruction and have favorable hemodynamic effects. The greatest benefit is observed when treatment is initiated within 48 hours after the onset of symptoms, but thrombolysis can still be effective in patients who have had symptoms for up to 14 days.[31] However, thrombolytic therapy carries a significant risk of bleeding. Pooled data from studies assessing various thrombolytic regimens showed that there was a 13% cumulative rate of major bleeding and a 1.8% rate of intracranial or fatal hemorrhage.[32] In weighing the clinical benefits against the risks of thrombolysis, the presence and severity of hemodynamic instability due to right ventricular failure appear to be the critical factors. A meta-analysis of five randomized trials that included patients with arterial hypotension or shock showed that thrombolysis effectively reduced the risk of death or recurrent pulmonary embolism (9.4%, vs. 19.0% with heparin alone;

Downloaded from www.nejm.org at UNIV MISSOURI on July 27, 2009 .
Copyright © 2008 Massachusetts Medical Society. All rights reserved.

Table 1. Anticoagulant Drugs for Initial Treatment of Pulmonary Embolism.*

Drug	Dose	Remarks
Unfractionated heparin (intravenous infusion)†	80 IU/kg of body weight as an intravenous bolus, followed by continuous infusion at the rate of 18 IU/kg/hr	Adjust infusion rate to maintain aPTT between 1.5 and 2.5 times control, corresponding to therapeutic heparin levels (0.3 to 0.7 IU/ml by factor Xa inhibition)‡; monitor platelet count at baseline and every other day from day 4 to day 14 or until heparin is stopped; investigate for heparin-induced thrombocytopenia if platelet count falls by ≥50% or a thrombotic event occurs.[28]
Low-molecular-weight heparins (subcutaneous injection)§		Low-molecular-weight heparins have not been tested in patients with arterial hypotension or shock and thus are not recommended for such patients; monitoring of anti–factor Xa levels may be helpful in patients at increased risk for bleeding, particularly those with moderate or severe renal impairment; the need for monitoring anti–factor Xa levels in pregnant women remains controversial; monitor platelet count at baseline and every 2 to 4 days from day 4 to day 14 or until heparin is stopped.¶
Enoxaparin	1.0 mg/kg every 12 hr or 1.5 mg/kg once daily‖	If creatinine clearance is <30 ml/min, reduce enoxaparin dose to 1 mg/kg once daily; consider unfractionated heparin infusion as an alternative.[13]
Tinzaparin	175 U/kg once daily	
Fondaparinux§	5 mg (body weight, <50 kg); 7.5 mg (body weight, 50–100 kg); or 10 mg (body weight, >100 kg), administered once daily	This drug is contraindicated in patients with severe renal impairment (creatinine clearance, <30 ml/min); no routine platelet monitoring is necessary.[28]

* The abbreviation aPTT denotes activated partial-thromboplastin time.
† Unfractionated heparin is the preferred treatment in patients with severe renal dysfunction (creatinine clearance, <30 ml per minute), since it is not eliminated by the kidneys, and in patients with an increased risk of bleeding (i.e., those with congenital or acquired bleeding diathesis, active ulcerative or angiodysplastic gastrointestinal disease, recent hemorrhagic stroke, recent brain, spinal, or ophthalmologic surgery, diabetic retinopathy, or bacterial endocarditis), owing to its short half-life and reversible anticoagulant effects.
‡ It is recommended that the treatment dose be adjusted on the basis of standardized nomograms such as that proposed by Raschke et al.[27]
§ Tinzaparin and fondaparinux are explicitly approved for the treatment of acute pulmonary embolism. Enoxaparin is approved for the treatment of deep-vein thrombosis with or without pulmonary embolism.
¶ This recommendation applies to postoperative patients and to medical or obstetrical patients who have received unfractionated heparin within the past 100 days.[28,29] For medical or obstetrical patients who have received only low-molecular-weight heparin, some authorities recommend no routine monitoring of platelet counts.[28]
‖ Once-daily injection of enoxaparin at a dose of 1.5 mg per kilogram is approved for inpatient treatment of pulmonary embolism in the United States and in some, but not all, European countries.

odds ratio, 0.45; 95% CI, 0.22 to 0.92; number needed to treat, 10).[30] Accordingly, thrombolysis is indicated in the case of patients with pulmonary embolism who have arterial hypotension or are in shock.[13,24] In contrast, the benefits of thrombolysis in patients with pulmonary embolism who have normal blood pressure are less well established. Results from a randomized trial suggested that selected patients with evidence of right ventricular dysfunction and a low risk of bleeding may benefit from early thrombolysis.[33] In that study, early treatment with alteplase plus heparin, as compared with conventional anticoagulation therapy, reduced the need for emergency therapeutic measures during the hospital stay; however, no benefit was found with respect to in-hospital mortality.

An overview of thrombolytic regimens for the treatment of pulmonary embolism is shown in Table 2, along with a list of absolute and relative contraindications to this type of treatment. Data from head-to-head trials indicate that the approved thrombolytic agents are equivalent in terms of the clinical outcomes; regimens with shorter infusion periods are thus preferred. Direct infusion of thrombolytic agents through a catheter in the pulmonary artery has not been shown to offer any advantages over systemic intravenous thrombolysis.[24]

SURGICAL AND INTERVENTIONAL TREATMENT OF PULMONARY EMBOLISM

For patients with arterial hypotension or shock in whom thrombolysis has failed or is absolutely contraindicated (Table 2), emergency surgical embolectomy can be a lifesaving treatment option, provided that the surgery can be performed on site

Downloaded from www.nejm.org at UNIV MISSOURI on July 27, 2009 .
Copyright © 2008 Massachusetts Medical Society. All rights reserved.

Table 2. Thrombolytic Agents and Regimens and Contraindications to Thrombolysis.

Agent	Regimen	Contraindications to Thrombolysis*
Streptokinase†	250,000 U as a loading dose over a 30-min period, followed by 100,000 U/hr over a period of 12–24 hr; accelerated regimen, 1.5 million IU over a 2-hr period‡	Absolute — history of hemorrhagic stroke or stroke of unknown origin, ischemic stroke in previous 6 mo, central nervous system neoplasms, major trauma, surgery, or head injury in previous 3 wk
Urokinase†§	4400 U/kg of body weight as a loading dose over a 10-min period, followed by 4400 U/kg over a period of 12–24 hr; accelerated regimen, 3 million U over a 2-hr period‡	Relative — transient ischemic attack in previous 6 mo, oral anticoagulation, pregnancy or first postpartum week, noncompressible puncture sites, traumatic resuscitation, refractory hypertension (systolic pressure, >180 mm Hg), advanced liver disease, infective endocarditis, active peptic ulcer
Alteplase†	100 mg over a 2-hr period¶; accelerated regimen, 0.6 mg/kg over a 15-min period	
Reteplase*‖	Two bolus injections of 10 U 30 min apart	
Tenecteplase**	30- to 50-mg bolus over a 5–10-sec period, adjusted for body weight (<60 kg, 30 mg; ≥60 to <70 kg, 35 mg; ≥70 to <80 kg, 40 mg; ≥80 to <90 kg, 45 mg; ≥90 kg, 50 mg)	

* The list of contraindications to thrombolysis has been adapted from guidelines for the management of acute myocardial infarction.[34] The contraindications apply to all thrombolytic agents.
† Unfractionated heparin should not be infused concurrently with streptokinase or urokinase; it can be given during alteplase or reteplase administration. Low-molecular-weight heparins have not been tested in combination with thrombolysis in patients with pulmonary embolism.
‡ Short (2-hour) infusion periods are generally recommended.
§ Urokinase is available in some European countries but not in the United States.
¶ This is the regimen approved by the Food and Drug Administration.
‖ This is an off-label use of reteplase.
** This is an off-label use of tenecteplase. The regimen listed here is the one recommended for patients with acute myocardial infarction. Preliminary evidence suggests that it is safe and effective in patients with pulmonary embolism as well.

or the patient can be referred promptly to a specialized tertiary center.[24,35] Surgical removal of pulmonary emboli is also generally recommended in the case of patients who have free-floating thrombi in the right atrium or ventricle and in the case of those with impending paradoxical embolism through a patent foramen ovale.[13] Alternatively, selected patients with hypotension or shock who cannot receive thrombolytic therapy may be candidates for percutaneous catheter thrombectomy.[36]

Inferior vena cava filters, which are used as a means of protection against recurrent venous thromboembolism, have been available for almost 40 years. Permanent filters are associated with long-term sequelae such as deep-vein thrombosis and the post-thrombotic syndrome.[37] The use of these filters in patients with pulmonary embolism is generally discouraged. On the other hand, the placement of retrievable venous filters may be considered when both the risk of recurrent pulmonary embolism and the risk of bleeding associated with anticoagulation are very high. This situation can occur, for example, in the case of a person with extensive thrombosis during the early postoperative period after neurosurgery or in the case of a pregnant woman who is thought to be within a few days of delivery.[13] The optimal duration of filter use is unknown; generally, filters should be removed as soon as it is safe to resume anticoagulation therapy.

TREATMENT STRATEGIES BASED ON SEVERITY

Non–High-Risk Pulmonary Embolism

Non–high-risk pulmonary embolism identifies an embolism in patients who have normal blood pressure on presentation. These patients have a low risk of death or complications during their hospital stay (Table 3). If pulmonary embolism is clinically suspected in a patient without hemodynamic compromise, it is advisable to initiate anticoagulant treatment with unfractionated or low-molecular-weight heparin while awaiting the results of further diagnostic tests. After confirmation of the diagnosis of pulmonary embolism on the basis of algorithms such as the one proposed in Figure 1, low-molecular-weight heparin or fondaparinux, given subcutaneously at weight-adjusted doses (Table 1) without routine monitoring of anti-Factor Xa, is the treatment of choice. As a rule, aggressive recanalization such as that attained

Downloaded from www.nejm.org at UNIV MISSOURI on July 27, 2009 .
Copyright © 2008 Massachusetts Medical Society. All rights reserved.

Table 3. Stratification of Risk of Death Associated with Pulmonary Embolism and Severity-Adjusted Treatment.*

Early Risk of Death	Risk Factor			Recommended Treatment
	Shock or Hypotension (on Clinical Examination)	Right Ventricular Dysfunction (on Echocardiography or Multidetector CT)	Myocardial Injury (on Cardiac Troponin Testing)	
High	Present	Present†	NA‡	Unfractionated heparin plus thrombolysis or embolectomy
Non-high				
Intermediate§	Absent	Present	Present	Low-molecular-weight heparin or fondaparinux; as a rule, no early thrombolysis; monitor clinical status and right ventricular function
	Absent	Present	Absent	
	Absent	Absent	Present	
Low	Absent	Absent	Absent	Low-molecular-weight heparin or fondaparinux; consider outpatient treatment

* Adapted with modifications from the 2008 Guidelines on the Diagnosis and Management of Acute Pulmonary Embolism of the European Society of Cardiology.[13] NA denotes not applicable.

† If RV function is normal on echocardiography, or if a CT scan shows no RV dilatation in a patient with hemodynamic compromise and clinically suspected pulmonary embolism, an alternative diagnosis should be sought.

‡ Troponin test results do not influence risk assessment or treatment in hemodynamically compromised patients with acute pulmonary embolism.

§ Although it has been suggested that normotensive patients with both RV dysfunction and myocardial injury have a higher risk of death than those with only one of these risk factors, there is currently no definitive proof that they should receive more aggressive treatment.

with early thrombolytic treatment is not recommended in patients with non–high-risk pulmonary embolism (Table 3).[30]

Intermediate-risk (submassive) pulmonary embolism identifies an embolism in a subgroup of normotensive patients who may have an elevated risk of death or serious complications if they present with right ventricular dysfunction or injury to the myocardium as a result of pressure overload. A number of echocardiographic findings (briefly mentioned in Fig. 2) have been used in cohort studies to establish the diagnosis of right ventricular dysfunction.[23] Although standardization of these findings was generally poor, the results of these studies and the post hoc analysis of data from a large registry[38] appear to confirm that right ventricular dysfunction detected on an echocardiogram may be an independent predictor of an adverse outcome. Retrospective data also suggest that detection of right ventricular enlargement on the four-chamber view of the CT scan is of prognostic relevance.[18,19] In addition, cardiac biomarkers, particularly troponins and natriuretic peptides, have been used to detect myocardial dysfunction and injury, respectively, in patients with acute pulmonary embolism.[39,40] These biomarkers have high negative predictive values (i.e., normal levels indicate a low risk of death or complications) but low positive predictive values, such that elevated levels alone do not dictate the need for aggressive early treatment other than anticoagulation therapy with heparin.

Currently, low-molecular-weight heparin or fondaparinux is considered to be adequate treatment for most normotensive patients with intermediate-risk pulmonary embolism (Table 3). However, early thrombolysis may be considered for selected patients who have a high risk of early death (due, for example, to preexisting heart failure or respiratory failure) and for whom thrombolytic agents are not contraindicated (Table 2).

High-Risk Pulmonary Embolism

High-risk (massive) pulmonary embolism is defined by the presence of cardiogenic shock, persistent arterial hypotension, or both. It accounts for 5% of all cases of pulmonary embolism and is associated with a high risk of in-hospital death, particularly during the first hours after admission.[3,41] For patients with suspected massive pulmonary embolism, a weight-adjusted bolus of unfractionated heparin should be administered immediately,

Downloaded from www.nejm.org at UNIV MISSOURI on July 27, 2009 .
Copyright © 2008 Massachusetts Medical Society. All rights reserved.

pending the results of further diagnostic tests. If the diagnosis of massive pulmonary embolism is confirmed on the basis of algorithms such as the one proposed in Figure 2, thrombolytic agents should be administered without delay. If thrombolysis is absolutely contraindicated or has failed, surgical embolectomy or catheter-based thrombus fragmentation or suction is a valuable alternative (Table 3).

AREAS OF UNCERTAINTY

At present, it remains unclear which additional imaging tests may be necessary to confirm or rule out a diagnosis of pulmonary embolism if the results of the CT scan are discordant with the pretest probability (negative CT angiogram despite high probability or vice versa). The appropriate treatment of patients with intermediate-risk pulmonary embolism also remains controversial. A large, multinational, randomized trial is currently under way to determine whether normotensive patients with right ventricular dysfunction, as detected on an echocardiogram or CT scan, and evidence of myocardial injury, as indicated by a positive troponin test, may benefit from early thrombolytic treatment (ClinicalTrials.gov number, NCT00639743). At the other end of the severity spectrum, outpatient treatment with low-molecular-weight heparin may be considered for patients with acute pulmonary embolism who have a particularly low risk of death or serious complications.[24] A prognostic model that considers demographic factors, coexisting conditions, and clinical findings at presentation has been reported to identify low-risk patients, with a negative predictive value approaching 99% (Table 2 in the Supplementary Appendix).[42,43] It remains uncertain whether a negative biomarker test (particularly for brain or N-terminal pro–brain natriuretic peptide, each of which has a very high negative predictive value for an adverse early outcome) should also be required before home treatment is considered.

New oral anticoagulants, including the direct thrombin inhibitor dabigatran and the factor Xa inhibitors rivaroxaban and apixaban, are currently being tested as alternatives to warfarin for long-term secondary prophylaxis against venous thromboembolism.

GUIDELINES

Guidelines for the management of acute pulmonary embolism have recently been published by the American College of Chest Physicians[24] and the European Society of Cardiology.[13] The management strategies proposed in this article are generally consistent with these guidelines.

CONCLUSIONS AND RECOMMENDATIONS

The diagnostic workup for patients with suspected pulmonary embolism should begin with an assessment of the clinical probability on the basis of validated explicit scores. When the probability is low or intermediate, a negative D-dimer test (level below 0.5 mg per liter) essentially rules out the diagnosis, whereas a positive result indicates the need for further testing, preferably multidetector CT scanning. The patient in the vignette had an intermediate clinical probability and a positive D-dimer test, and a multidetector CT scan confirmed the diagnosis of pulmonary embolism. Anticoagulation therapy should thus be initiated promptly; I would use a low-molecular-weight heparin or fondaparinux because of the proven efficacy, greater ease of use, and better safety profile of each of these agents as compared with unfractionated heparin. The detection of right ventricular dilatation on the patient's CT scan indicates the presence of an intermediate-risk pulmonary embolism. Early thrombolytic therapy should be considered, but its role in such cases remains uncertain, and I would be inclined not to use it in this case, given the negative troponin test. I would wait to initiate warfarin therapy until the second or third hospital day, to ensure that right ventricular dysfunction does not progress to hemodynamic instability, a situation that would warrant late thrombolysis. I would discontinue heparin once the INR has been in the therapeutic range (between 2.0 and 3.0) with warfarin therapy for 2 consecutive days.

Dr. Konstantinides reports receiving lecture fees from Boehringer Ingelheim, CSL Behring, GlaxoSmithKline, and Sanofi-Aventis. No other potential conflict of interest relevant to this article was reported.

An audio version of this article is available at www.nejm.org.

Downloaded from www.nejm.org at UNIV MISSOURI on July 27, 2009 .
Copyright © 2008 Massachusetts Medical Society. All rights reserved.

REFERENCES

1. Silverstein MD, Heit JA, Mohr DN, Petterson TM, O'Fallon WM, Melton LJ III. Trends in the incidence of deep vein thrombosis and pulmonary embolism: a 25-year population-based study. Arch Intern Med 1998;158:585-93.
2. Anderson FA Jr, Wheeler HB, Goldberg RJ, et al. A population-based perspective of the hospital incidence and case-fatality rates of deep vein thrombosis and pulmonary embolism: the Worcester DVT Study. Arch Intern Med 1991; 151:933-8.
3. Kasper W, Konstantinides S, Geibel A, et al. Management strategies and determinants of outcome in acute major pulmonary embolism: results of a multicenter registry. J Am Coll Cardiol 1997;30: 1165-71.
4. Carson JL, Kelley MA, Duff A, et al. The clinical course of pulmonary embolism. N Engl J Med 1992;326:1240-5.
5. Goldhaber SZ, Visani L, De Rosa M. Acute pulmonary embolism: clinical outcomes in the International Cooperative Pulmonary Embolism Registry (ICOPER). Lancet 1999;353:1386-9.
6. Office of the Surgeon General. Acting Surgeon General issues 'call to action to prevent deep vein thrombosis and pulmonary embolism.' September 2008. (Accessed December 1, 2008, at http://www.surgeongeneral.gov/news/pressreleases/pr20080915.html.)
7. Tapson VF. Acute pulmonary embolism. N Engl J Med 2008;358:1037-52.
8. Wells PS, Anderson DR, Rodger M, et al. Excluding pulmonary embolism at the bedside without diagnostic imaging: management of patients with suspected pulmonary embolism presenting to the emergency department by using a simple clinical model and D-dimer. Ann Intern Med 2001; 135:98-107.
9. Le Gal G, Righini M, Roy PM, et al. Prediction of pulmonary embolism in the emergency department: the revised Geneva score. Ann Intern Med 2006;144:165-71.
10. van Belle A, Büller HR, Huisman MV, et al. Effectiveness of managing suspected pulmonary embolism using an algorithm combining clinical probability, D-dimer testing, and computed tomography. JAMA 2006;295:172-9.
11. Stein PD, Fowler SE, Goodman LR, et al. Multidetector computed tomography for acute pulmonary embolism. N Engl J Med 2006;354:2317-27.
12. Stein PD, Woodard PK, Weg JG, et al. Diagnostic pathways in acute pulmonary embolism: recommendations of the PIOPED II Investigators. Radiology 2007; 242:15-21.
13. Torbicki A, Perrier A, Konstantinides SV, et al. Guidelines on the diagnosis and management of acute pulmonary embolism: the Task Force for the Diagnosis and Management of Acute Pulmonary Embolism of the European Society of Cardiology (ESC). Eur Heart J 2008;29:2276-315.
14. Perrier A, Roy P-M, Sanchez O, et al. Multidetector-row computed tomography in suspected pulmonary embolism. N Engl J Med 2005;352:1760-8.
15. Kruip MJ, Slob MJ, Schijen JH, van der Heul C, Büller HR. Use of a clinical decision rule in combination with D-dimer concentration in diagnostic workup of patients with suspected pulmonary embolism: a prospective management study. Arch Intern Med 2002;162:1631-5.
16. Righini M, Aujesky D, Roy PM, et al. Clinical usefulness of D-dimer depending on clinical probability and cutoff value in outpatients with suspected pulmonary embolism. Arch Intern Med 2004;164: 2483-7.
17. Perrier A, Howarth N, Didier D, et al. Performance of helical computed tomography in unselected outpatients with suspected pulmonary embolism. Ann Intern Med 2001;135:88-97.
18. van der Meer RW, Pattynama PM, van Strijen MJ, et al. Right ventricular dysfunction and pulmonary obstruction index at helical CT: prediction of clinical outcome during 3-month follow-up in patients with acute pulmonary embolism. Radiology 2005;235:798-803.
19. Schoepf UJ, Kucher N, Kipfmueller F, Quiroz R, Costello P, Goldhaber SZ. Right ventricular enlargement on chest computed tomography: a predictor of early death in acute pulmonary embolism. Circulation 2004;110:3276-80.
20. Hunsaker AR, Zou KH, Poh AC, et al. Routine pelvic and lower extremity CT venography in patients undergoing pulmonary CT angiography. AJR Am J Roentgenol 2008;190:322-6.
21. Anderson DR, Kahn SR, Rodger MA, et al. Computed tomographic pulmonary angiography vs ventilation-perfusion lung scanning in patients with suspected pulmonary embolism: a randomized controlled trial. JAMA 2007;298:2743-53.
22. Kucher N, Goldhaber SZ. Management of massive pulmonary embolism. Circulation 2005;112(2):e28-e32.
23. Sanchez O, Trinquart L, Colombet I, et al. Prognostic value of right ventricular dysfunction in patients with haemodynamically stable pulmonary embolism: a systematic review. Eur Heart J 2008;29:1569-77.
24. Kearon C, Kahn SR, Agnelli G, Goldhaber S, Raskob GE, Comerota AJ. Antithrombotic therapy for venous thromboembolic disease: American College of Chest Physicians Evidence-Based Clinical Practice Guidelines (8th edition). Chest 2008; 133:Suppl:454S-545S. [Erratum, Chest 2008; 134:892.]
25. Quinlan DJ, McQuillan A, Eikelboom JW. Low-molecular-weight heparin compared with intravenous unfractionated heparin for treatment of pulmonary embolism: a meta-analysis of randomized, controlled trials. Ann Intern Med 2004; 140:175-83.
26. The Matisse Investigators. Subcutaneous fondaparinux versus intravenous unfractionated heparin in the initial treatment of pulmonary embolism. N Engl J Med 2003;349:1695-702. [Erratum, N Engl J Med 2004;350:423.]
27. Raschke RA, Gollihare B, Peirce JC. The effectiveness of implementing the weight-based heparin nomogram as a practice guideline. Arch Intern Med 1996; 156:1645-9.
28. Warkentin TE, Greinacher A, Koster A, Lincoff AM. Treatment and prevention of heparin-induced thrombocytopenia: American College of Chest Physicians Evidence-Based Clinical Practice Guidelines (8th edition). Chest 2008;133:Suppl:340S-380S.
29. Arepally GM, Ortel TL. Heparin-induced thrombocytopenia. N Engl J Med 2006;355:809-17.
30. Wan S, Quinlan DJ, Agnelli G, Eikelboom JW. Thrombolysis compared with heparin for the initial treatment of pulmonary embolism: a meta-analysis of the randomized controlled trials. Circulation 2004;110:744-9.
31. Daniels LB, Parker JA, Patel SR, Grodstein F, Goldhaber SZ. Relation of duration of symptoms with response to thrombolytic therapy in pulmonary embolism. Am J Cardiol 1997;80:184-8.
32. Konstantinides S, Marder VJ. Thrombolysis in venous thromboembolism. In: Colman RW, Marder VJ, Clowes AW, George JN, Goldhaber SZ, eds. Hemostasis and thrombosis: basic principles and clinical practice. 5th ed. Philadelphia: Lippincott Williams & Wilkins, 2006:1317-29.
33. Konstantinides S, Geibel A, Heusel G, Heinrich F, Kasper W. Heparin plus alteplase compared with heparin alone in patients with submassive pulmonary embolism. N Engl J Med 2002;347:1143-50.
34. Van de Werf F, Ardissino D, Betriu A, et al. Management of acute myocardial infarction in patients presenting with ST-segment elevation: the Task Force on the Management of Acute Myocardial Infarction of the European Society of Cardiology. Eur Heart J 2003;24:28-66.
35. Leacche M, Unic D, Goldhaber SZ, et al. Modern surgical treatment of massive pulmonary embolism: results in 47 consecutive patients after rapid diagnosis and aggressive surgical approach. J Thorac Cardiovasc Surg 2005;129:1018-23.
36. Kucher N. Catheter embolectomy for acute pulmonary embolism. Chest 2007; 132:657-63.
37. Decousus H, Leizorovicz A, Parent F, et al. A clinical trial of vena caval filters in

Downloaded from www.nejm.org at UNIV MISSOURI on July 27, 2009 .
Copyright © 2008 Massachusetts Medical Society. All rights reserved.

the prevention of pulmonary embolism in patients with proximal deep-vein thrombosis. N Engl J Med 1998;338:409-15.
38. Kucher N, Rossi E, De Rosa M, Goldhaber SZ. Prognostic role of echocardiography among patients with acute pulmonary embolism and a systolic arterial pressure of 90 mm Hg or higher. Arch Intern Med 2005;165:1777-81.
39. Klok FA, Mos IC, Huisman MV. Brain-type natriuretic peptide levels in the prediction of adverse outcome in patients with pulmonary embolism: a systematic review and meta-analysis. Am J Respir Crit Care Med 2008;178:425-30.
40. Becattini C, Vedovati MC, Agnelli G. Prognostic value of troponins in acute pulmonary embolism: a meta-analysis. Circulation 2007;116:427-33.
41. Kucher N, Rossi E, De Rosa M, Goldhaber SZ. Massive pulmonary embolism. Circulation 2006;113:577-82.
42. Jiménez D, Yusen RD, Otero R, et al. Prognostic models for selecting patients with acute pulmonary embolism for initial outpatient therapy. Chest 2007;132:24-30.
43. Aujesky D, Roy PM, Le Manach CP, et al. Validation of a model to predict adverse outcomes in patients with pulmonary embolism. Eur Heart J 2006;27:476-81.
Copyright © 2008 Massachusetts Medical Society.

COLLECTIONS OF ARTICLES ON THE *JOURNAL*'S WEB SITE

The *Journal*'s Web site (**www.nejm.org**) sorts published articles into more than 50 distinct clinical collections, which can be used as convenient entry points to clinical content. In each collection, articles are cited in reverse chronologic order, with the most recent first.

Downloaded from www.nejm.org at UNIV MISSOURI on July 27, 2009 .
Copyright © 2008 Massachusetts Medical Society. All rights reserved.